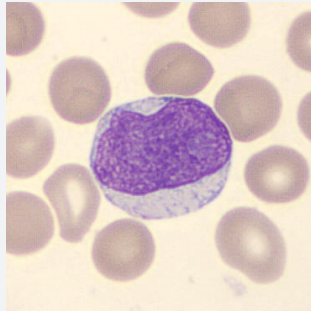


CellCase

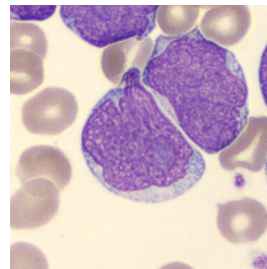
NUMBER 24



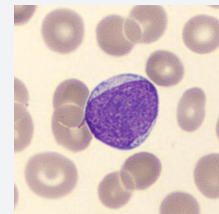
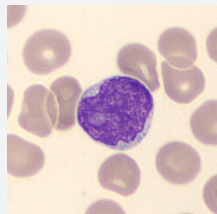
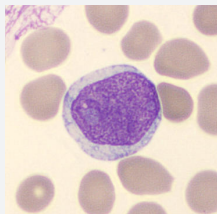
A 83-year old man was admitted to the emergency ward because of aberrant laboratory results during a routine check-up after a recent gastric bleeding.

Results from the cell counter:

Hemoglobin: 10,3 g/dL
Thrombocyte count: $100 \times 10^9/L$
Leukocyte count: $250 \times 10^9/L$



Peripheral blood smear analysis revealed the following lymphocytes:



What is your diagnosis?