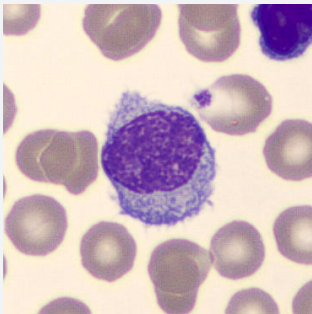


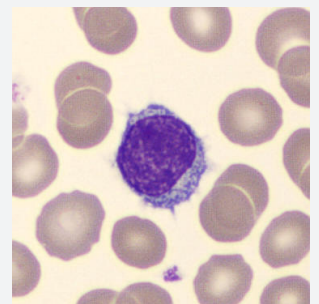
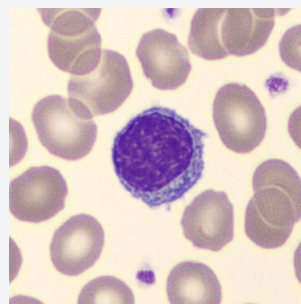
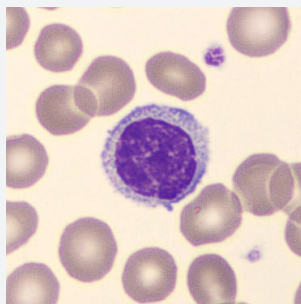
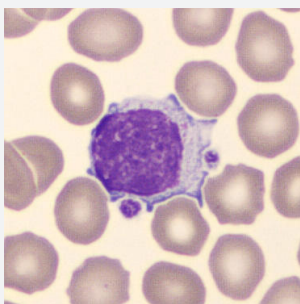
CellCase

NUMBER 26



A blood sample from a 90-year old asymptomatic woman was analyzed. The result from the cell counter showed abnormalities.

The following cells were found in the blood smear:



What is your diagnosis?