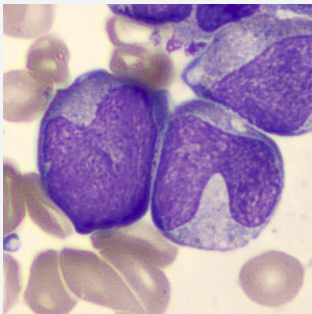


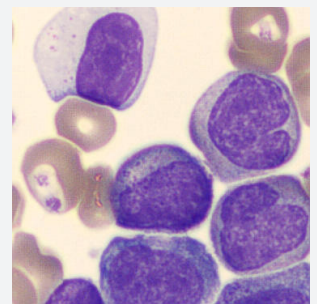
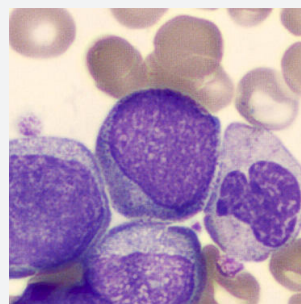
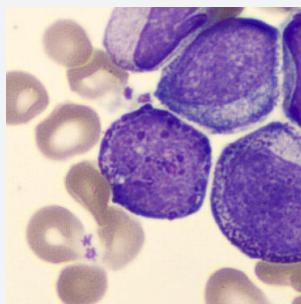
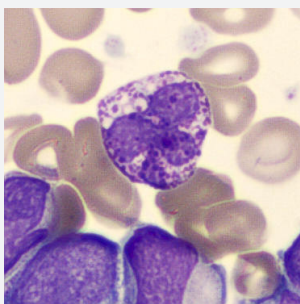
# CellCase

## NUMBER 27



A 72-year old woman was admitted in the emergency ward because of fatigue, weight loss and stomach complaints. The cell counter displayed an anemia, slight thrombocytosis and a severe leukocytosis.

Peripheral blood smear displayed the following cell classes:



## What is your diagnosis?